

ནང་ལྷོ་བ་དག་ཚུ་ཚོ་གསལ་བ།

Patient Care Association

PCA Patients' Report on January 2017

Age	Sex	Department	Hospital	Distance (km)
21	M	Dermatology	AIIMS	18-19
2	M	Cardiology	AIIMS	18-19
44	M	Hepatology	Max Hospital	22
44	M	Hepatology	Max Hospital	22
52	F	Mammalogy	Max Hospital	22
43	M	ENT	AIIMS	18-19
11	F	Dermatology	AIIMS	18-19
54	F	Gastroenterology	AIIMS	18-19
23	F	Endocrinology	AIIMS	18-19
23	M	Orthopaedics, rheumatology, ophthalmology	AIIMS	18-19
38	M	Oncology	AIIMS	18-19
8	F	Orthopaedics	AIIMS	18-19
38	M	Gastroenterology	AIIMS	18-19
29	F	Genecology	AIIMS	18-19

Totally patients in January 2017: 14

New patients: 8

44 y/o, male, hepatology case (2)

Diagnosis: hepatic steatosis

Diagnostics: full body check-up

Treatment: medication

Current condition: stable

Hospital: Max Hospital

Distance: 22 km

52 y/o, female, mammalogy case

Diagnosis: left breast lump

Diagnostics: full body check-up, mammography

Treatment: medication

Current condition: stable

Hospital: Max Hospital

Distance: 22 km

43 y/o, male, ENT case

Diagnosis: left side nasal deviation

Diagnostics: sleep test

Treatment: continue prescribed medication

Current condition: stable

Hospital: AIIMS

Distance: 18-19 km

11 y/o, female, dermatology case

Diagnosis: verruca vulgaris

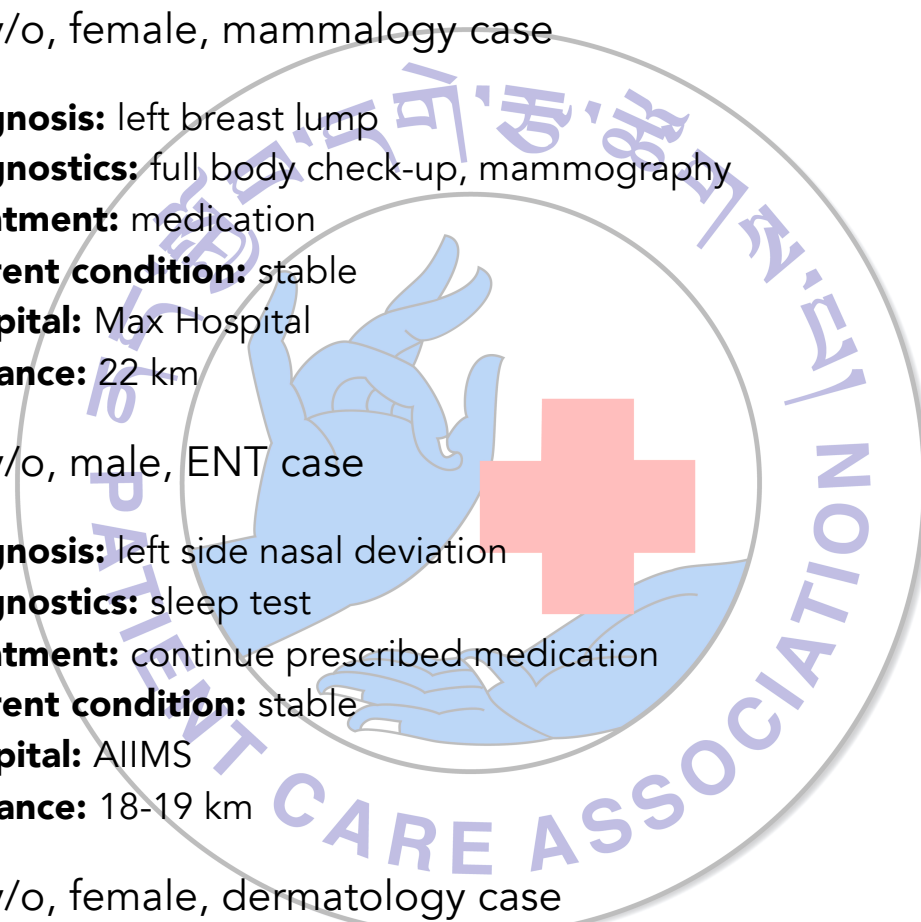
Diagnostics: wart examination

Treatment: radiofrequency ablation (RFA)

Current condition: stable

Hospital: AIIMS

Distance: 18-19 km



54 y/o, female, gastroenterology case

Diagnosis: gastritis

Diagnostics: blood test, CT scan, palpation

Treatment: medication

Current condition: stable

Hospital: AIIMS

Distance: 18-19 km

23 y/o, female, endocrinology case

Diagnosis: goitre, enlarged thyroid

Diagnostics: fine-needle aspiration test (FNAC)

Treatment: medication

Current condition: stable

Hospital: AIIMS

Distance: 18-19 km

38 y/o, male, oncology case

Diagnosis: tongue cancer

Diagnostics: NA

Treatment: continue radio- and chemo-therapy

Current condition: stable

Hospital: AIIMS

Distance: 18-19 km

8 y/o, female, orthopaedic case

Diagnosis: spastic quadreplegia

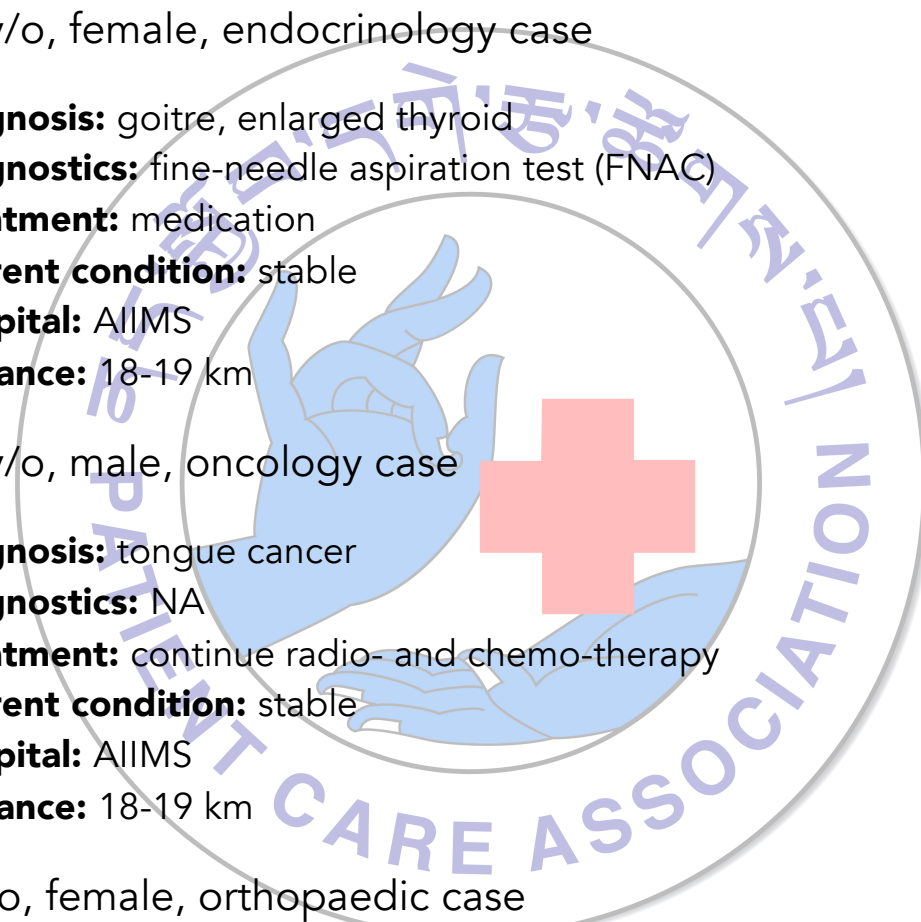
Diagnostics: NA

Treatment: medication and plan for multiple surgeries

Current condition: stable

Hospital: AIIMS

Distance: 18-19 km



38 y/o, male, gastroenterology case

Diagnosis: NA

Diagnostics: in progress

Treatment: NA

Current condition: unstable/urgent

Hospital: AIIMS

Distance: 18-19 km

29 y/o, female, gynecology case

Diagnosis: candidiasis, bartholin cyst

Diagnostics: HBs PPBS, Hb, CBC

Treatment: elective surgery is required

Current condition: stable

Hospital: AIIMS

Distance: 18-19 km

