

Monthly Report of Patient Care Trust

October -2017

Total Patients: 21

Age	Sex	Department	Hospital
53	Male	Oncology	AIIMS
41	Female	Gastroenterology	AIIMS
44	Male	General Physician	Max Hospital and AIIMS
29	Female	Surgery	AIIMS
2	Male	Paediatric	Telemedicine
54	Female	ENT and Medicine	AIIMS
28	Male	Surgery	AIIMS
72	Male	Cardiology	AIIMS
50	Male	Gastroenterology	Fortis
68	Male	GI Surgery and Gastroenterology	AIIMS
45	Female	Gastroenterology	AIIMS
44	male	Endocrinology	AIIMS
36	Female	Neurology	IHBAS
45	Female	Gastroenterology	AIIMS
38	Male	Neurology	AIIMS
51	Female	Cardiology	AIIMS
72	Male	Pulmonary	AIIMS
41	Male	Dermatology	Max and St. Stephen
26	Male	Surgery	Gangaram
25	Female	Gynaecology	AIIMS
49	Female	Psychiatric	AIIMS

Patient Details

October, 2017

Total Patients: 21

53, Male, Oncology

Diagnosis: Lung Cancer

Diagnostics: CBC, PET CT, CT Scan, Blood test

Treatment: Chemotherapy

Current condition: Under treatment

Hospital: AIIMS

41, Female, Gastroenterology

Diagnosis: Hepatitis-B

Diagnostics: HbsAg+HBU DNA, HbeAg, AFP, LFT, CBC, USG and Fibro scan

Treatment: Medication

Current condition: Ambulatory

Hospital: AIIMS

44, Male, General Physician

Diagnosis: Grave's Disease

Diagnostics: ENT Endoscopy

Treatment: Medication

Current condition: Ambulatory

Hospital: Max Hospital and AIIMS

29, Female, General Surgery

Diagnosis: Small Lump

Diagnostics: USG Breast

Treatment: Medication

Current condition: Stable

Hospital: AIIMS

2, Male, Pediatric


Diagnosis: NA

Diagnostics: NA

Treatment: Medication

Current condition: Stable

Hospital: Tele medicine



54, Female, ENT and Medicine

Diagnosis Cancer

Diagnostics: Mouth Endoscopy, Full body checkup

Treatment: Medication

Current condition: Stable

Hospital: AIIMS and Fortis

28, Male, Surgery

Diagnosis: Budd-Chiari syndrome

Diagnostics: USG Doppler, Blood test, PAC

Treatment: Medication and surgery

Current condition: Medical

Hospital: AIIMS

72, Male, Cardiology

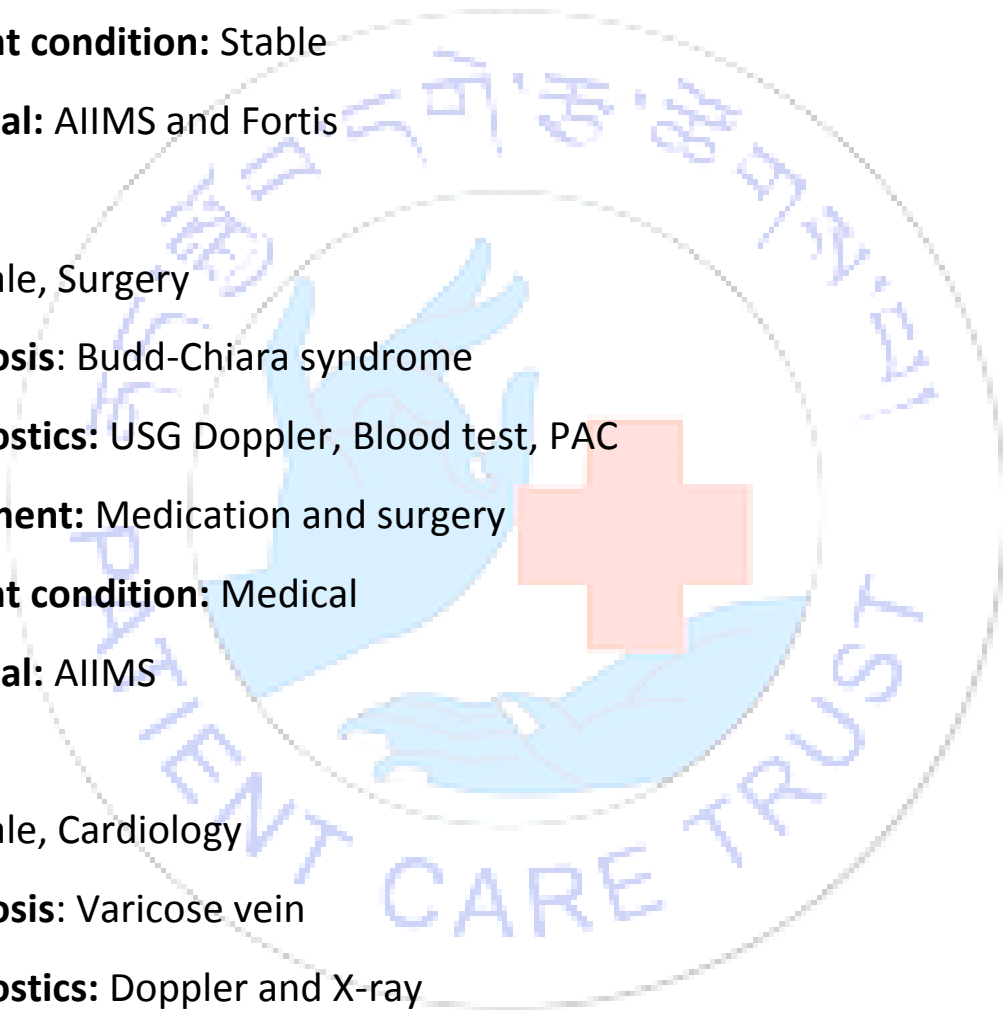
Diagnosis: Varicose vein

Diagnostics: Doppler and X-ray

Treatment: IFT, EPS, Endovenous laser ablation

Current condition: Stable

Hospital: AIIMS



50, Male, Gastroenterology

Diagnosis: LCD, HVB

Diagnostics: USG, CBC, KFT

Treatment: Medication

Current condition: Stable

Hospital: Fortis

68, Male, Surgery, Gastroenterology and pulmonary

Diagnosis: Dysphagia, Esophageal

Diagnostics: Endoscopy, Bronchoscopy, Hematology, CT scan

Treatment: ERCP, Medication

Current condition: Critical

Hospital: AIIMS

45, Female, Gastroenterology

Diagnosis: Depression

Diagnostics: USG

Treatment: Medication

Current condition: Stable

Hospital: AIIMS

44, Male, ENT and Endocrinology

Diagnosis: Grave's Disease

Diagnostics: Blood test, Endoscopy of ENT

Treatment: Medication

Current condition: Stable

Hospital: AIIMS

36, Female, Neurology

Diagnosis: Epilepsy, Seizure disorder

Diagnostics: Doctor consulted

Treatment: Medication

Current condition: Stable

Hospital: AIIMS

45, Female, Gastroenterology and Oncology

Diagnosis: Hepatitis-B, Cervical Cancer

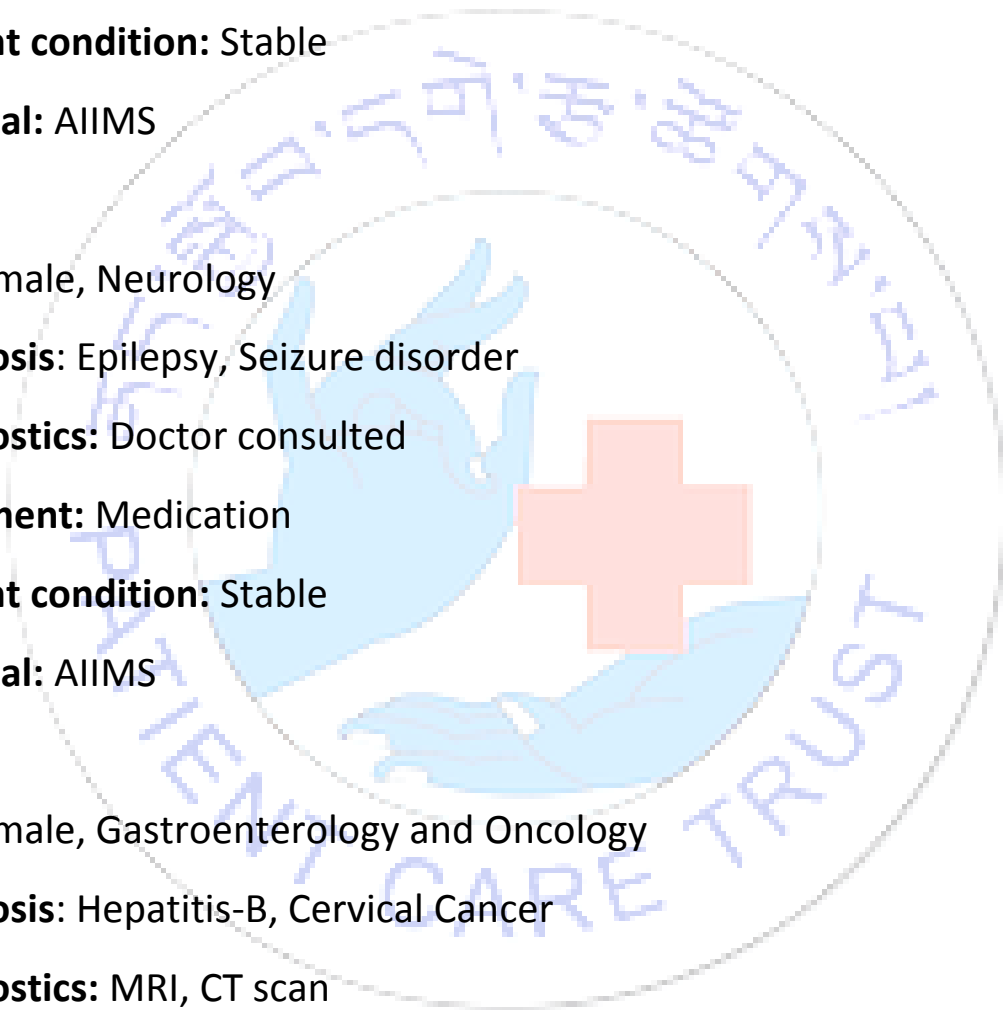
Diagnostics: MRI, CT scan

Treatment: Radio and Chemotherapy

Current condition: Stable

Hospital: AIIMS

38, Male, Neurology



Diagnosis: Sleep disorder

Diagnostic: N/A

Treatment: Medication

Current condition: Stable

Hospital: AIIMS

51, Female, Cardiology

Diagnosis: GSV dilation

Diagnostic: USG Doppler

Treatment: EVLA

Current condition: Stable

Hospital: AIIMS

72, Male, Pulmonary

Diagnosis: Small cell carcinoma lung

Diagnostic: CECT, USG, X-ray

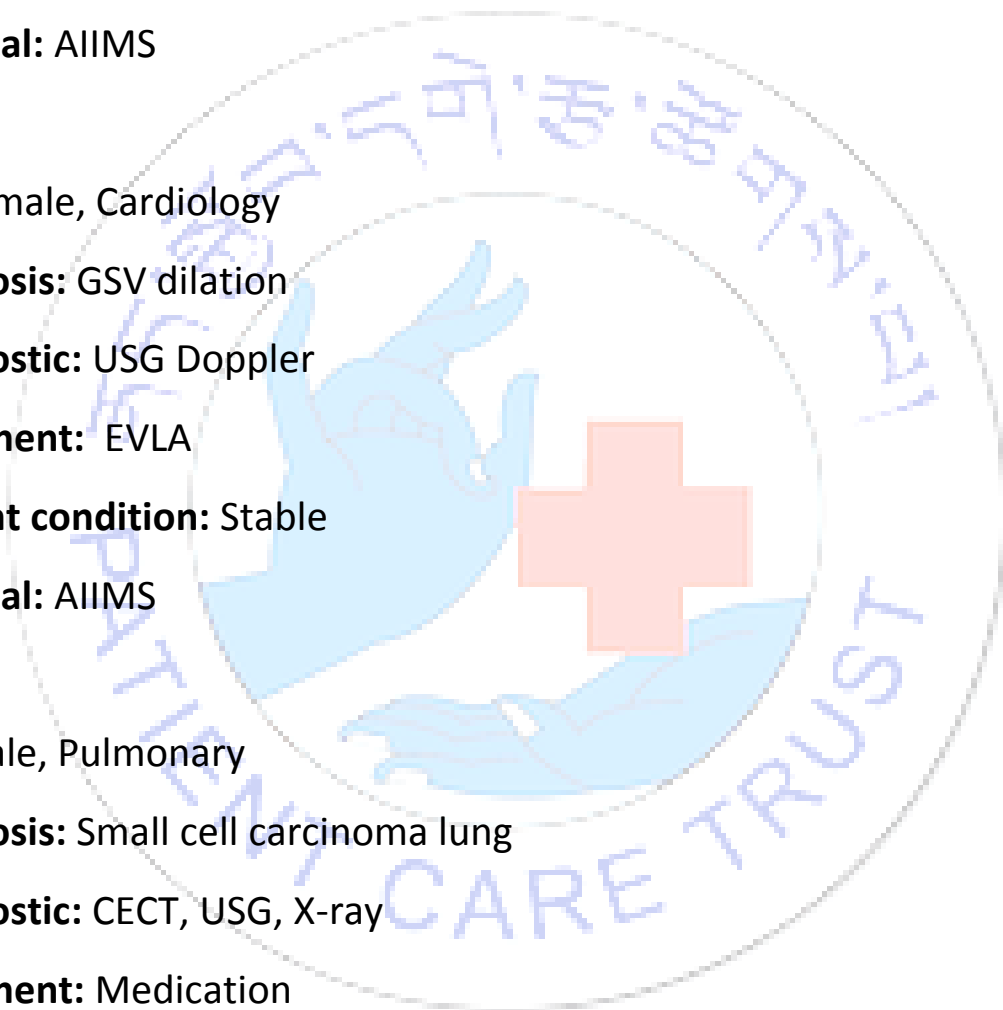
Treatment: Medication

Current condition: Stable

Hospital: AIIMS

41, Male, Dermatology

Diagnosis: Skin rashes



Diagnostic: X-ray, Full body check up

Treatment: Not yet started

Current condition: Stable

Hospital: Max hospital, AIIMS

26, Male, Surgery and Gastroenterology

Diagnosis: Intestinal TB

Diagnostic: X-ray, Sputum test, USG

Treatment: Medication

Current condition: Critical

Hospital: Shri Ganga ram Hospital

25, Female, Gynecology

Diagnosis: Uterus cyst

Diagnostic: USG

Treatment: Yet to start

Current condition: Stable

Hospital: AIIMS

29, Female, Psychiatric

Diagnosis: Depression

Diagnostic: N/A

Treatment: Under medication

Current condition: Stable

Hospital: AIIMS



